

SPLINTS

By Garry Kaufman

How serious are they? Four case studies reveal common misunderstandings about this leg injury.

The term 'splint' comes from splint bone, one of two rather small, almost non-supporting bones, one of which lies on either side of the cannon bone. Each a mirror image of the other; they are long, slender, wedge-shaped bones, finger-sized at the top just below the knee (carpal joints), and tapering to a beaded point about two-thirds of the way down the cannon bone. Each is held closely to the cannon bone by a tough, thin ligament that extends nearly its entire length. Because one is located on the inside back corner of the cannon bone and the other on the outside back corner, together they form a protective trough for the suspensory ligament and, in part, the deep flexor tendon of both the front and rear leg.

Here are several case histories that show just how varied the actual problem can be. In each case, the owner described the problem as a splint because it appeared as a peanut-sized lump on the inside of the cannon bone on a front leg; but in reality, only one case turned out to be an actual splint. (Keep in mind that similar cases could involve the outside splint bone of either the front or hind leg since the arrangement anatomy is basically the same.)

Case 1:

A yearling Quarter Horse filly was found in her exercise paddock showing severe left forelimb lameness, and with an obvious swelling in the splint area. The owners expressed particular concern not only because of the filly's value, but also because they had owned a previous horse whose show career had been cut short by a fractured splint bone that had healed poorly. They wondered if this splint was going to cause a permanently thickened leg like the one the horse they had developed. This filly, however, was able to walk normally, and even though the lump was getting larger by the minute, the swelling was soft and fluctuant. Thumb pressure produced a pitted area which would again fill when the thumb was removed. This involved area was not over the splint bone, but rather an area just under the skin (subcutaneous) and slightly behind the splint bone. Summary: the filly had been playing, and had bumped the leg and ruptured a subcutaneous blood vessel. She did not have a splint, and the injury healed, leaving no blemish. The owners' concern, however, was understandable. Although the permanent thickness of a splint is a blemish rather than unsoundness, it can be devastating to a show career in halter competition where a clean-legged appearance is essential.

Case 2:

A yearling Thoroughbred colt was brought in from pasture with what looked like a splint on the left front leg. Although no lameness was present, thumb pressure applied to the lump caused obvious pain. The swelling was located exactly in the groove between the cannon bone and the splint bone, indicating involvement of the ligament holding the splint bone to the cannon bone. Closer explanation was then made by holding the leg up, thereby taking tension off the suspensory ligament and deep

flexor tendon. In this case, no further swelling could be found by tracing with the finger tips the inside border of the splint bone as it lies along the suspensory ligament and deep flexor tendon. Summary: this colt did have a splint. But its underlying cause was more important than the fact he did, indeed, have a splint that would be a blemish, and that he was temporarily lame.

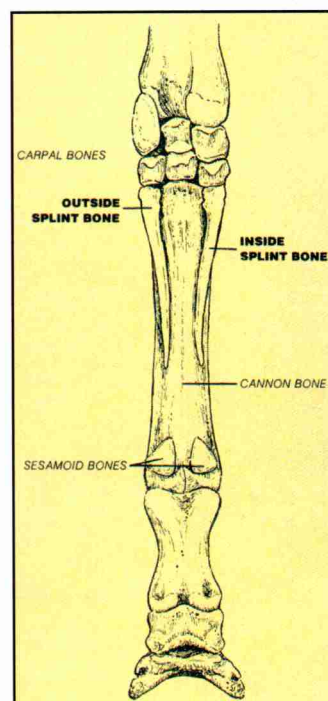
flexor tendon. In this case, no further swelling could be found by tracing with the finger tips the inside border of the splint bone as it lies along the suspensory ligament and deep flexor tendon. Summary: this colt did have a splint. But its underlying cause was more important than the fact he did, indeed, have a splint that would be a blemish, and that he was temporarily lame.

Usually, splints don't merely happen. Several factors can contribute to them, such as soft, growing bones and immature ligaments. But, all too often improper conformation of the knee (carpus) and cannon bone is the real underlying reason. In this Thoroughbred colt, an examination of the entire leg revealed a rather severe, offset (crooked) knee conformation. This was present in both front legs, but more pronounced in the left. He had 'popped the splint' because stress had been placed in an abnormal location. The lump that resulted was nature's way of reinforcing this area. In this case, the stress line drawn from the shoulder down the limb will run through the knee and quite often through the swelling of the splint. This type of splint will often reoccur as further stresses are added to the limb during training, and might be represented by several lumps along the groove between the splint bone and the cannon bone. This case was treated with therapeutic cautery (firing) to increase circulation to the area for more complete healing, because of the likelihood of reoccurrence.

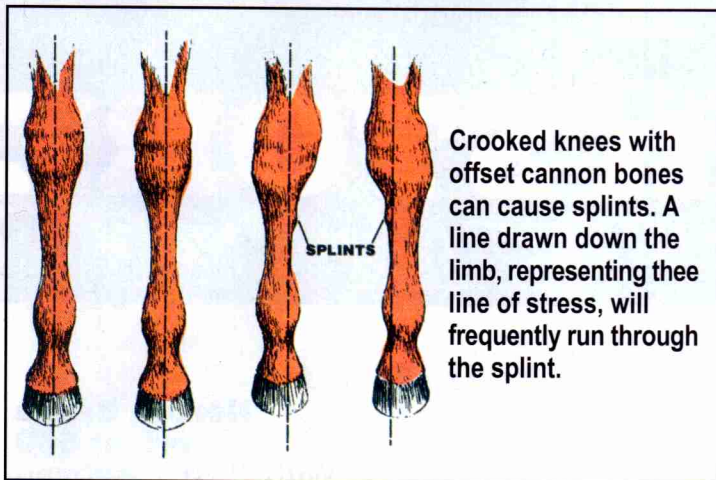
Case 3:

A 2 year old Quarter Horse colt was found in his stall with what looked like a splint on his right front leg. The colt had been exercised daily for several weeks and had been apparently normal the day before the examination. No lameness was present when he was trotted in a straight line, but the lameness became apparent when he was trotted in a small circle to the left.

Closer examination showed the lump to be on the cannon bone itself, just slightly in front of the groove between the cannon and splint bone. Local anesthetic placed in and around the swelling eliminated the lameness. Follow-up X rays confirmed the presence of a small, saucer-shaped fracture in the cannon bone. The splint



Rear view of the left front leg



bone was not involved, and, of course, a splint was not present. Summary: this case is a good example of why most fractures occur in the inside surface of the cannon bone, as well as in the rather fragile splint bone. A discussion with the trainer concerning the exercise programme was revealing. The colt was exercised on a 20-foot lunge line once a day for 20-30 minutes. No other exercise was available to him. He naturally looked forward to the chance to get out of the stall, and when released would charge to the end of the line, bucking, kicking, and circling at a dead run. Because he was led to the exercise ring from the left (near) side, he was circled to the left first, then to the right for the second half of the exercise period. He was allowed to exercise out of control; and the momentum of the circling had carried the inside edge of his left hoof into the tight cannon bone, and a rather serious injury had resulted.

Whether exercised on a line or turned loose to run and play, horses kept in stalls use absolutely no common sense when they exercise. Too often this recklessness ends in serious, sometimes fatal, injury. While exercise is a very important part of the daily routine, it must be controlled exercise.

Case 4:

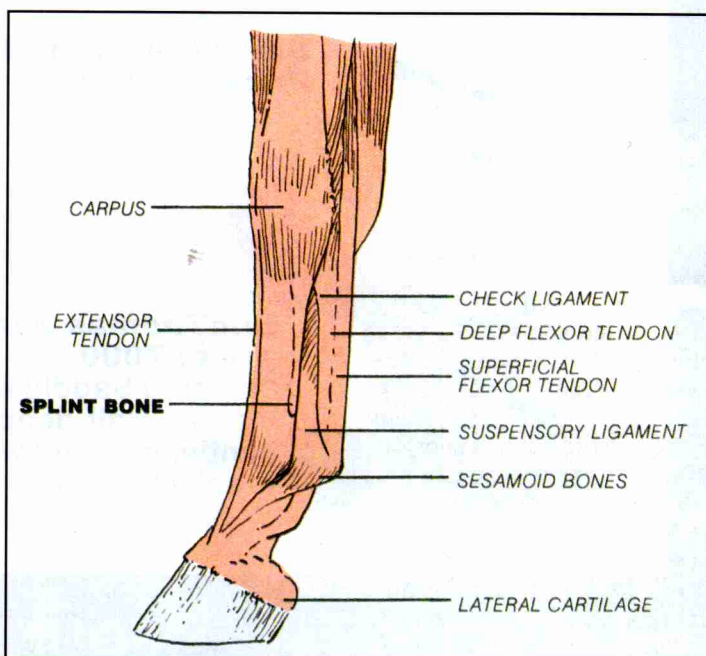
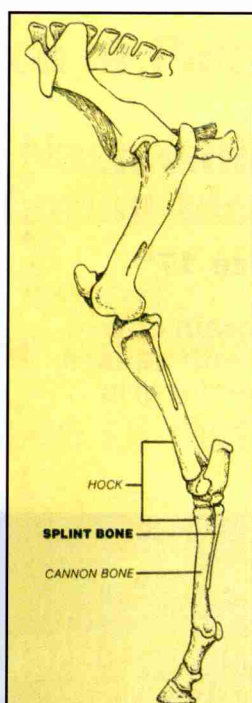
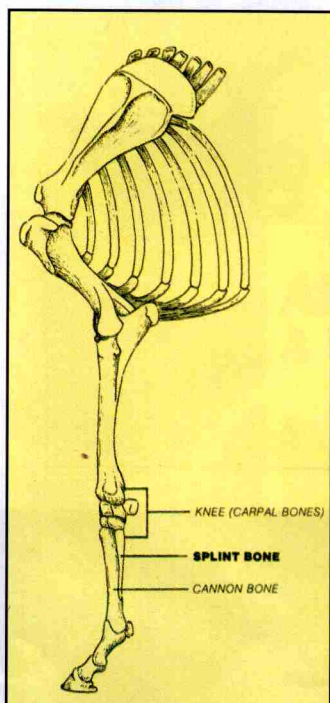
A 5 year old Arabian stallion was submitted for examination of a lump on the right forelimb; the trainer suspected a splint. The stud was in park horse training and had exhibited an occasional lameness in the right front since the appearance of a lump several weeks prior examination. However, for the most

part, he was moving sound in both training sessions and in the show ring.

The trainer had elected to continue training and showing, using special leg protectors to pad the splint bone area. It was only when the lump started increasing in size and lameness persisted for more than a few steps during a training session that a closer examination was required.

Finger tip examination with the knee (carpal joints) in a flexed position and the leg held up revealed an extension of the swelling along the inner (tendon) border of the splint bone, as well as the obvious outside swelling. Thumb pressure on the splint bone below the lump as well as over the swelling itself cause pain. Pressure applied to the swelling on the inner border also elicited a pain response. Because no lameness was present during the examination, no nerve blocking was performed. Follow-up X rays showed a fracture line extending diagonally through the splint bone, not a splint. Summary: the stallion required surgery to correct the lameness. The real area of concern was the swelling that couldn't be seen. The callus and the tissue buildup bridging the fracture line on the deep (tendon) side of the splint bone was causing ever-increasing irritation along the suspensory ligament and deep flexor tendon. The pain that resulted was alleviated by removing the callus, scar tissue buildup, and entire portion of the splint bone below the fracture line. Surgery required a general anesthetic and a 14-week recovery period.

How serious are lumps that look like splints? It depends on what the problem really is. Learn what structures are involved. The anatomy in this area is clear-cut and simple. The anatomy of the hind limb is the same below the hock in this area as it is below the carpus in the front. It is the same on the inside of the leg as it is on the outside. Yet the condition causing the lump can vary dramatically, and each treatment must fit the particular situation. If the lump is a genuine splint, it might cause no lameness whatsoever, and all but the most serious problems involving splints are temporary. But this doesn't take away from the loss suffered if the problem arises at a critical time in training, showing, or racing. Splints are costly and damaging to a career whenever the horse's ability to function, even if lameness is temporary. ■



The splint bones lie on either side of the suspensory ligament and deep flexor tendon and form a protective trough. Splints can occur anywhere along this area.